

Summarised from *Journal of Clinical Periodontology* Volume 47, issue 5 (May 2020), 640-648

Editors: Phoebus Madianos & Andreas Stavropoulos, EFP scientific affairs committee

**Rapporteurs:**

Lee Sand Ming, Samantha Nina Marie Ramos Uy, with Dr George Pelekos

**Affiliation:**

Postgraduate programme in periodontology and implant dentistry, University of Hong Kong

*study*

# Promising long-term implant survival of TSFE without graft in reduced residual bone heights

**Authors:**

Peter Rammelsberg, Samuel Kilian, Christopher Busch, Stefanie Kappel

## Background

Dental-implant placement in the posterior maxilla often requires sinus-floor elevation because of insufficient bone height. Augmentation can be performed via either lateral-window or transcrestal sinus-floor elevation (TSFE), where graft material is placed below the Schneiderian membrane. In both approaches, high implant survival rates of up to five years have been reported.

As a less invasive approach, TSFE has been recommended when bone height is 6mm and above. Its advantages include less post-operative morbidity and a more tolerable post-operative course compared to lateral-window augmentation.

Limitations of sinus-floor augmentation with bone-graft materials have been reported. These include significant graft resorption over time and donor-site morbidity. Consequently, some clinicians have come to prefer using only blood clots, as new bone formation has been observed even without grafting. Two systematic reviews of sinus augmentation with or without grafting revealed mean implant survival rates of 96% and above.

The selection of the appropriate sinus-augmentation technique is based on residual bone height. Lateral-window augmentation is recommended for severe cases with residual bone height of less than 5mm. There is little reported information on the effect of substantially reduced bone height on TSFE and the risk of long-term implant failure.

## Aims

The aim of this study was to evaluate the long-term survival of implants with transcrestal sinus-floor elevation (TSFE) without graft in subjects with different residual bone heights below the sinus floor. The relation between long-term implant survival and the residual bone height was also evaluated.

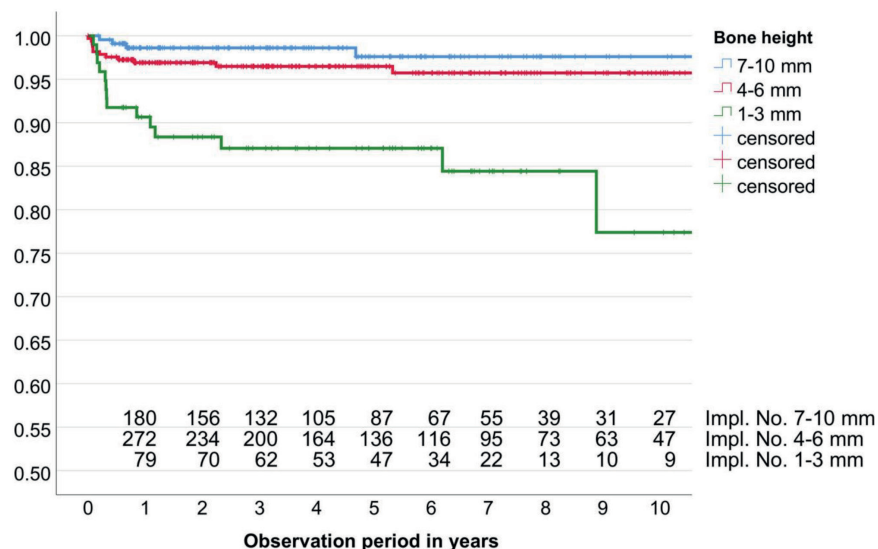
## Materials & methods

- This was a retrospective observational cohort study which included implants that fulfilled the specified criteria.
- There were 648 implants in the test group (TSFE without graft) and 674 in the control group (maxillary implant on native bone).
- All implants (Straumann and Nobel Biocare) placed were 10mm in length, with diameter range of 3.3–5.0mm.
- A stent with a 7mm standardised pin was used to determine the axis of the implant position, while the lowest bone height of the implant site was determined using a digital panoramic X-ray.
- All implants were placed using a standardised transcrestal approach. Membrane perforation was determined by monitoring the membrane's elasticity using a depth gauge and, if perforation was present, the implant was placed without additional treatment.
- All implant insertions were by hand ratchet. Transverse ridge expansion was done by spreading the ridge in sites with insufficient bone width, to achieve at least 1mm of native bone around implants.
- Both groups were prescribed 2g amoxicillin one hour before surgery. The TSFE group additionally received 3 x 1g amoxicillin for 6-7 days.
- Surgical sites were excluded from oral hygiene for a week. Suture removals were done 6-9 days after surgery. All implants were placed or supervised by four experienced dentists.
- Descriptive data between two groups were compared. Implant survival over time was analysed with Kaplan-Meier survival curves and compared.
- The association of implant survival over time with bone height and membrane perforation was assessed.
- The number of implants at risk reduced significantly over the 10-year period, which may affect the precision of analysis. In severely reduced residual bone heights (1-3mm), survival analysis shows a sharp decrease within the first year because of early implant failure from lack of osseointegration. These sites also demonstrate lower long-term survival compared to residual bone heights > 4mm.

## Figure:

Kaplan-Meier survival curves for implants placed in combination with TSFE with different initial bone height.

The effect of transcrestal sinus-floor elevation without graft on the long-term prognosis of maxillary implants



## Results

- When comparing implant and patient characteristics, the variables with statistically significant difference were implant type (Straumann TL, Straumann BL, Nobel Biocare), lateral ridge expansion (yes/no), and implant location (posterior/anterior).
- Fifty-eight implant failures occurred (30 in test, and 28 in control): 38 early failures through lack of osseointegration (24 in test, and 14 in control) and 20 late failures because of peri-implantitis (18) or implant fractures (two).
- Difference in probability of 10-year implant survival between the test (93.7) and control (92.9%) groups was not significant.
- Females demonstrated a significantly lower incidence of failure, while age, TSFE, additional lateral-ridge expansion, and location had no significant effect.
- The incidence of perforation of the Schneiderian membrane during implant placement increased as the bone height decreased. Perforations occurred in 6.7% of sites with a bone height of > 6mm, 15.4% in 4-6mm, and 24.4% in 1-3mm.
- Analyses showed a slightly reduced probability of 10-year survival following membrane perforation (89.6% compared to 94.2% in sites without perforation).
- The survival probability significantly reduced as the bone height decreased (97.6% in bone heights > 6mm, 95.7% in 4-6mm, and 77.4% in 1-3mm).
- The variable of bone height demonstrated a protective effect, with a hazard ratio of 0.642. This means that the greater the residual bone height, the better the survival.

## Limitations

- Retrospective design with unreported data regarding the initial number of implants placed and possible attrition bias.
- Questionable comparability of the groups: most of the implants in the control group were placed in the anterior sector (46.7%). Anterior implant placement often presents with adequate bone height, so there is less likely to be a need for TSFE.
- Selection of solely 10mm implant length limits applicability of results to other implant lengths.
- Residual bone-height calculation using 2D measurements may yield unprecise values because of anatomical superimposition and other reasons. This ultimately raises the question of the standard of care for TSFE/implant treatment planning.

## Conclusions & impact

- Implant placement done by TSFE without graft does not present a higher risk of failure compared to implant placement in native bone in the maxilla.
- As the residual bone height is reduced, the probability of implant survival decreases and the incidence of membrane perforation increases.
- TSFE without graft in bone heights > 6mm demonstrates an outstanding 97.6% 10-year probability of survival and exhibits a reduced – yet still encouraging – probability of 95.7% in bone heights of 4mm-6mm.
- It is still uncertain whether membrane perforation is a risk factor for implant survival.
- The study gives an insight on the minimum residual bone height needed for TSFE with 10mm implants without the use of bone graft. In reduced bone heights (4mm-6mm), there is reasonable long-term survival. In severely reduced sites (1mm-3 mm), a steep decrease in survival is noted, with 77.4% survival at 10 years.



JCP Digest 77, published in July 2020, is a summary of the article 'The effect of transcrestal sinus floor elevation without graft on the long term prognosis of maxillary implants.' J Clin Periodontol. 2020; 47 (5), 640-648.



<https://www.onlinelibrary.wiley.com/doi/epdf/10.1111/jcpe.13278>



Access through EFP members' page log-in: <http://efp.org/members/jcp.php>